

EFFECTS OF CRYOLIPOLYSIS ON ABDOMINAL ADIPOSITY OF WOMEN

Patricia Froes Meyer*, Anne Caroline Guarines Furtado, Sayonara Fatima Tomaz Morais, Luis Gonzaga de Araujo Neto, Rodrigo Marcel Valentim da Silva, Melyssa Lima Medeiros and Claudete Arruda Maciel de Queiroz.

Potiguar University, Department of physiotherapy, Natal, Brazil.

Patricia Froes Meyer, Rua Maxaranguape 550 apto 2603 Tirol, Natal, RN, Brasil – CEP: 59020160.

*Corresponding author email: patricia.froesmeyer@gmail.com

Abstract

BACKGROUND: The cryolipolysis is on the spotlight as a non-invasive method which reduces fat layer thickness with no damage to surrounding tissues. **OBJECTIVE:** This study aims to verify the effectiveness of cryolipolysis in the reduction of localized adiposity in women. **MATERIALS AND METHODS:** This is an experimental study, without a control group, with pre and post treatment evaluation through a single application on the lower abdominal area. **Setting:** Research conducted in the period from July to December 2015 at the University Potiguar. **Participants:** A group of 15 women, age between 25-50 years. The cryolipolysis was used in the following parameters: temperature (-7°C); suction power (30 kPa), and application time (60 min). **Measurements:** After the cryolipolysis was performed, a follow-up of 2 months was conducted to verify the changes related to weight, body circumference, fat layer thickness, which were evaluated by ultrasonography and photogrammetry. **RESULTS:** From data analysis, the reductions observed on perimeter ($p=0.03$) and ultrasonography ($p=0.03$) showed significant results, considering $p<0.05$. As of body weight results ($p=0.57$), the average value varied during the study; however, at the end of the research, no significant weight increase or decrease was reported, as it is known that this method does not interfere with this variable. Additionally, quantitative data were satisfactory. The photogrammetry analysis showed that cryolipolysis positively affected subjects' results. **CONCLUSION:** A change in body contouring, especially in individuals with lower body mass, reinforces the idea that the parameters must be suitable for individual needs.

Keywords: Adipose tissue, adiposity, photogrammetry, cryolipolysis

INTRODUCTION

One of the most popular techniques for body measure reduction is the liposuction. Although it is a minimally invasive surgery, various complications may occur. The most common complications include infection, necrosis, fibrosis, bleeding, hematoma, seroma, lymphoedema, pulmonary embolism, and venous thrombosis profunda. (1)

Nevertheless, the number of surgical procedures has decreased, while the demand for non-invasive techniques has grown. The results of these techniques are less visible and not immediate; however, they do not have the level

of risk and secondary effects associated to a surgery. (2)

In addition, calorie-reduced diets and/or exercise and a variety of resources have been used, aiming lipolysis and consequent reduction of excess localized fat. However, most treatments are improperly conducted or they do not have scientific evidence or validation. (3)

The cryolipolysis is a noninvasive method of selective reduction of body fat. This non-surgical procedure uses controlled cooling to reduce subcutaneous fat tissue without causing damage to surrounding tissues. (4) The equipment maintains the default temperature below 0°C during the application. Sensors

incorporated within the cooling plates are located in each side of applicator. (5) Thus, the cold will induce an inflammation mechanism which causes the death of adipocytes and, as a consequence, gradually reduces the fat layer. (6, 7)

The cooling causes a selective and progressive reduction of the fat tissue by means of programmed death, causing eventual apoptosis by inflammation. (8) The effects of cryolipolysis are not immediate; however, in two months, a statistically significant reduction is possible, with about 14.67% decrease in local fat thickness. (9)

The cryolipolysis is not a treatment for obesity, but for those who have discreet localized fat which persists despite diets and physical activity. This procedure presents few possibilities for complications or health risks, since fat is gradually eliminated by phagocytosis and does not increase lipid levels in the blood. (8) Since it is not an invasive method, it is less risky and more time / cost-effective, and avoids the physical and psychological suffering accompanying fat-lowering surgeries such as liposuction.

Although there are studies proving the effectiveness of cryolipolysis, this research aims to investigate the action of cryolipolysis equipment on localized adiposity on women, seeking more knowledge about the technique and its mechanism of action on women's localized adiposity.

MATERIALS AND METHODS

The study was characterized as a quasi-experimental research, which compared "first and last" results and it was submitted to the Ethics Committee (protocol number 1,249,981), as stated in Resolution 196/69 of the National Health Council.

The selection of subjects was made by non-probabilistic convenience, and the population consists of patients of the Integrated Health Clinic (IHC) at the Potiguar University (UNP) in Natal - RN/Brazil. The group consisted of 15 participants who were treated with a single application of cryolipolysis in the lower abdominal area.

The group consisted of randomly chosen female participants, within the age range of 25-50 years old, sedentary, with localized abdominal adiposity, with comprehension capacity and preserved body sensitivity.

Individuals who had no time to be submitted to the proposed procedures, as well as those suffering from cold allergy (Raynaud's syndrome) and who have presented more than 2 kg weight changes during the research were excluded from the study group, since cryolipolysis does not interfere in this variable. Significant changes in weight refer to other factors, which may interfere in the overall result.

The instruments used to collect data in this research was the Localized Adiposity Physiotherapy Assessment Protocol (LAPAP), validated by Meyer et al. (10), in which the following topics are considered: patient identification, physical examination, weight, height, BMI, skinfold thickness and circumference measurement. For cryolipolysis, the Cryo Redux (Advice, Brazil) was used. For adiposity evaluation, a high-frequency ultrasound device (12MHZ) Model XL, (Samsung, South Korea); a Sony Cyber-shot camera, model DSC-W350, Brasil; a tape measure and Fiber Glicomed scale, USA were used.

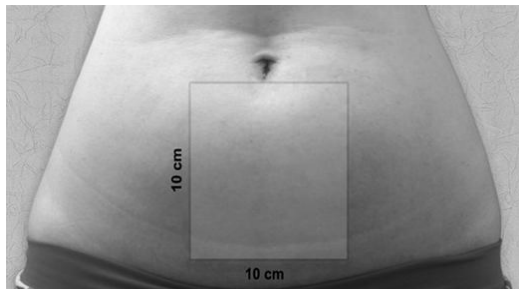
Upon participants' selection, they were informed about the procedures to which they would be submitted and signed a consent form. Then subjects underwent the LAPAP protocol for general data collection, anthropometric data evaluation, and for abdominal circumference measurement, which was performed with the patient in a standing position and with the measuring tape positioned 5 cm below the umbilicus, parallel to the ground.

The pictures were taken with patients in a standing position, sideways (right and left) and frontal and they were asked to make a full, voluntary shoulder flexion (full arm lift above the head). All participants wore bikini or intimate clothing for data collection and during the cryolipolysis procedure. The camera used for all photos was the same and it was placed on a tripod at the height of 76 cm from the ground and at a distance of 44 cm from the subject. The photos were taken in three stages of treatment: on the first evaluation and after thirty and sixty days of the cryolipolysis procedure.

Later, they were submitted to ultrasound examination, performed by a specialist. The infraumbilical abdominal region was examined with subjects in supine position in an area of 10x10 cm, which was marked with a pen, just below the navel, as shown in Figure 1. Ultrasonography was performed in S. multifrequency linear mode with probe depth

frequency ranging from 24 to 31 Hz, Breast L5 - 13IS, 4 to 6.5 cm penetration, coupling the probe longitudinally and transversely, with no mechanical pressure, in order to obtain data regarding the adipose tissue layer thickness and density, and the inflammatory and fibrosis processes. Three ultrasound examinations were performed in each patient: before cryolipolysis and after thirty and sixty days of treatment.

Figure 1. Area of cryolipolysis ultrasound on subjects



The acceptance of cryolipolysis application was voluntary, with subjects in the supine position, with body inclination at 45° and was performed with a 10-cm-wide applicator, which was positioned in the same area where the ultrasound was performed, just below the umbilicus. The application parameters were: temperature -7°C (according protocol suggested by Chopra et al. (11), pressure of 30 kPa and the exposure time was 60 min, with the hydrating protective blanket over the treated area.

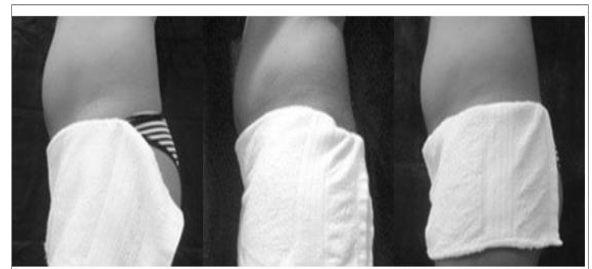
The treatment consisted of one single application of cryolipolysis in all participants. Reassessment was performed during two months to evaluate related changes to body adiposity of studied area.

At the end of the two-month-follow-up, of photogrammetry evaluation was conducted, in which eleven experts evaluated the changes in body contour identified in eleven pictures of volunteers and according to results evaluation of, results were graded from 0 to 10. The material sent to professionals consisted of six images of the abdominal area before treatment and thirty and sixty days after the procedure, them being three frontal view takes and three profile takes, as shown below. Therefore, each participant would be observed in two different perspectives and could then receive a maximum score of 20 points. Figure 2 shows the three frontal photogrammetry pictures.

Figure 2. A, B, C: Front view, cryolipolysis before (A) and after 30 (B) and 60 days (C). The patient did not significantly change the weight during treatment.

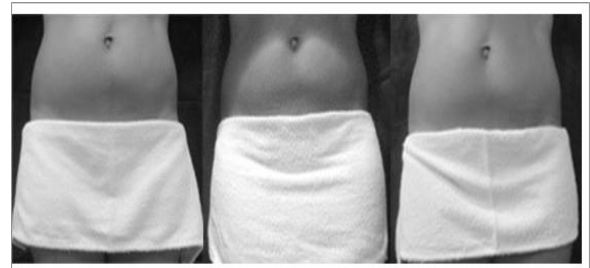

Figure 3. A, B, C: Side view photogrammetry, same subject as Figure 2.



For data analysis, the Wilcoxon test ratings were applied, with reference to the value of $p < 0.05$ in order to verify the normality and the significance of the data. With the aid of the test, the weight, circumference, fat layer thickness, inflammation and the appearance of fibrosis were analyzed, the last three being analyzed by ultrasound examination. It was compared before and after 30 and 60 days after the procedure.

The photos taken in the evaluations were embedded in Word document and sent to eleven evaluators. This assessment, called photogrammetry, suggested by Mendonça et al. (12), has the function to examine possible signs of clinical improvement with the aid of photos of before and after the procedures, to assess the effects of cryolipolysis in adipose tissue. For the verification of the photos, a descriptive analysis was conducted and the frequency distribution was presented in percentages.

RESULTS

The study was performed with the volunteering of 15 women of age mean of 35 years; 1.59 ± 0.05 m height; weight and BMI 8.24 Kg $63.94 \pm 22.56 \pm 5.87$ Kg /m². Four participants were excluded from the study for

losing more than 2 kg during the research, resulting in the final number of 11 evaluated subjects. Table 1 below shows the data relating to the height, weight and BMI before the procedure.

Table 1. Descriptive analysis of subjects' height, weight and BMI before cryolipolysis.

					Standard
	N	Minimum	Maximum	Mean	deviation
Height	11	1.49	1.56	1.59	0.05
Weight					
(before)	11	53	74	63.94	8.24
BMI	11	19.47	26.35	22.56	5.87

The studied group was heterogeneous as far as weight, circumference and fat density were concerned; however, despite any judgment, there was no interference in the results, although the application of cryolipolysis followed a unique pattern with no individualized parameters due to equipment limitation, which did not offer temperature settings for different fat layers.

Quantitative analysis

For the quantitative analysis, three variants were used: weight, body circumference and ultrasonography, the last with reference to the fat layer thickness, given in centimeters (cm). The findings and the correlation between the data variations are presented in Table 2 below, where a reduction of the three variables in the first month of the study is evident, but the ultrasonography only presented significant values during this period. By the end of the 60-day-period, an increase in average weight was noticed, but it was not significant in the overall results. An increase in the ultrasound values and a reduction in circumference was also reported, but with no significant impact in results.

Table 2. Results of the weight, abdominal circumference and ultrasonography before the procedure and after 30 and 60 days from cryolipolysis, considered significant when $p < 0.05$.

	Before	30 days	60 days	P value (30 days)	P value (60 days)
Weight	63.94 ± 8.73	56.90 ± 22.2	63.72 ± 18.22	0.30	0.57
Circumference	91.59 ± 6.67	91.18 ± 8.22	82.16± 6.96	0.31	0.03*
Ultrasonography	3.11± 0.99	2.50± 0.60	2.70± 0.70	0.03*	0.03*

* There is significant difference with $p < 0.05$

Qualitative analysis

In the qualitative analysis, the ultrasonography results showed the presence of inflammation and the onset of fibrosis in the stimulated area. The data analysis was based in the medical report, which ranked the intensity of these processes as absent, mild, moderate and severe. Table 3 shows the inflammatory process quantification. It was noticed that before the application, none of the volunteers showed signs of inflammation in the adipose layer. Inflammation was present during the two months of research; however, it was more intense in the first thirty days. Nevertheless, this response was statistically relevant in the first month, $p=0.003$, and in the second month, $p=0.004$ (reference value $p < 0.05$).

Table 3. Quantification of inflammation before and 30/60 days after cryolipolysis.

Percentage (N=11)			
Level of inflammation	Before	30 days	60 days
Absent	0%	0 %	9.1 %
Mild	0%	18.2%	54.5%
Moderate	0%	27.3%	36.4%

Another expected reaction after the cryolipolysis process is the appearance of fibrosis⁴; however, some patients already presented fibrosis before treatment. In some cases, the adipose tissue is stiff because the collagen of fibrotic septa in the middle of the fat tissue is very dense. This fibrosis may be constitutional and of genetic origin or may be resulting from previous surgeries or even from other aesthetic treatments. (13)

In this study, in opposition to the inflammation process, fibrosis was more intense only in the second month; however, the changes relating to fibrosis had no relevant statistical values in the first month ($p=0.79$) and the second month ($p=0.52$), with reference value of $p<0.05$. Table 4 quantifies the percentage of existing adiposity septa before cryolipolysis and the level of fibrosis which appeared after treatment.

Table 4. Quantification of fibrosis before and 30 / 60 days after the cryolipolysis procedure.

Percentage (N=11)			
Fibrosis level	Before	30 days	60 days
Absent	18.2%	18.2%	18.2%
Mild	9.1%	36.4%	36.4 %
Moderate	72.6%	27.3%	45.5 %
Severe	6.7%	18.2%	0.0%

Figure 4 shows the ultrasonography images of one of the patients at three stages: before procedure (4A) and thirty (4B) and sixty days (4C) after treatment. It is possible to see the

physiological responses caused by cryolipolysis as an inflammatory process, which appears as a whitish area. This is the image that appears at the top of Figure 4B.

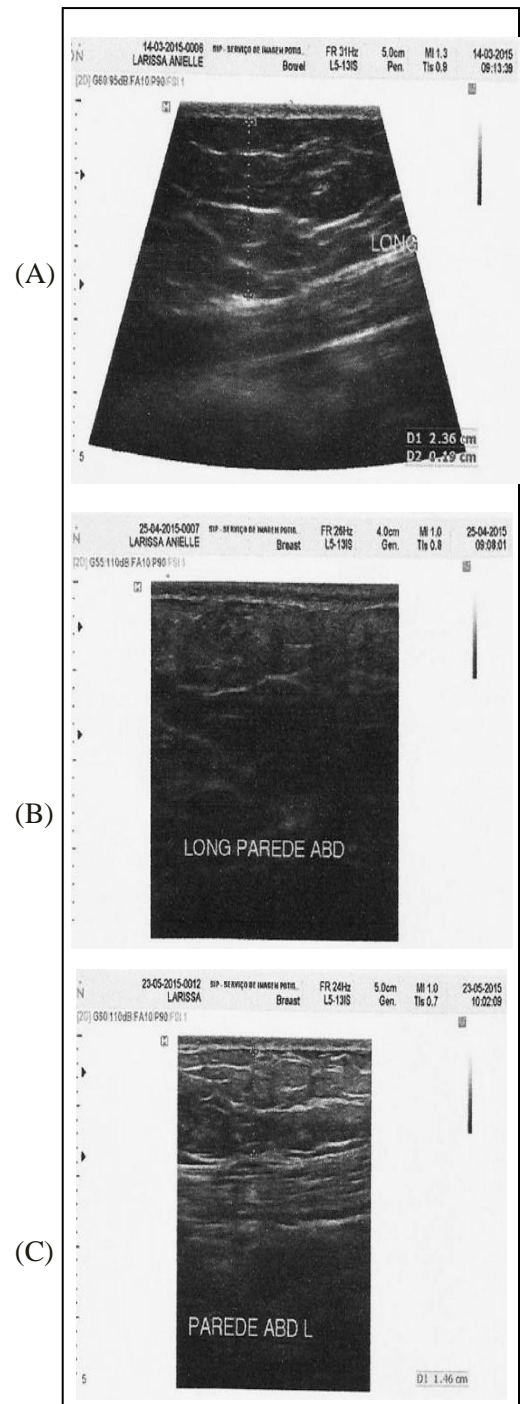


Figure 4. Ultrasound results of patient submitted to cryolipolysis. Before (A) and after 30 (B) and 60 days (C). In the Figure 4A and 4C it is possible to perceive the white lines that are the fibrous septa that are located in the middle of the hypodermic tissue. It can be seen that in figure 4B there is no presence of septa, probably due to the process of phagocytosis that happens around 30 days. It is possible to see larger numbers of septa in Figure 4C precisely because in 60 days the presence of fibroses is greater.

Photogrammetry analysis

An assessment was carried out to supplement data using photogrammetry, aiming to compare results before and after the procedure and to visualize the effects of cryolipolysis in adipose tissue through volunteers' photographs.

Each participant received grades ranging 0-10 according to the results presented in the pictures. The average grades for frontal pictures of 6,38+ notes were 2.82 and profile was 4.82 + 2.96, with divergent views as to the results obtained, however, out of the 121 given grades for each angle, 86% of the evaluators agree that there was a reduction in fat in front view photos and 73.6% noticed an improvement in profile takes.

DISCUSSION

During this research, collected data allowed quantitative and qualitative evaluations of the effects of cryolipolysis in adipose tissue and it was possible to notice changes in the weight of subjects, their waist circumference, fat layer thickness, in the contour of their body and with respect to inflammation and fibrosis in the treated area

At the end of data collection, it was noted that despite weight fluctuations, the average change was not statistically significant, corroborating with what is versed in literature (14), as the cryolipolysis is a local procedure which does not interfere in this variable.

Regarding the abdominal circumference, obtained results were according to expected, as it occurred in studies from other authors, who got positive results in reducing it without weight loss. Ferraro et al. (8), who applied the cryolipolysis in 50 patients with different body sizes. Fourteen volunteers were submitted to abdominal cryolipolysis, and the significant average 6.86-cm- abdominal girth reduction was observed, even though the body weights of patients remained constant throughout the treatment, suggesting reduction of the fat layer resulting from the procedure.

Zelickson et al. (15) also confirmed the reduction in circumference in a study done with a group of 42 participants, in which a significant reduction in waist circumference of 0,9cm was recorded, proven by ultrasonography images. The same author also reports that there was no significant change in weight.

Brightman and Geronemus (16) contributed with their study in which two applications of cryolipolysis were performed in a single patient in the region of the flanks. Before treatment, one subject weighed 202 lbs (91.6 kg) and had 97 cm of waist circumference. After 10 weeks, the circumference decreased to 96.4 cm, moment which a second application of cryolipolysis was performed. Five months after the second application the participant had a girth of 94.6 cm and weighed 204 lbs (92.5 kg). At the end of treatment, it a loss of 2.4 cm in abdominal girth was observed, despite weight gain.

With the findings obtained through the ultrasonography examination, it was possible to quantify a significant reduction in the fat layer which received treatment with cryolipolysis, corroborating with other studies, (17) In these, an application of cryolipolysis on the side of thighs in 37 subjects was performed and fat loss progress was recorded by ultrasonography (2.6 mm average reduction). The fat layer thickness, when treated with cryolipolysis, may suffer a reduction, which varies from 10.3% to 25.5% when analyzed by ultrasonography. (14)

Therefore, the data above demonstrates that both qualitative and quantitative results occurred after application of cryolipolysis in most patients. A study which examines the clinical pre-and post-treatment photographs of provided visible reduction evidence in the inner thigh contour, 16 weeks after a single cycle of treatment with cryolipolysis, which is in line with the findings of this investigation.(15) Coleman et al.(18) also observed a reduction in the contour of 6 volunteers of his research, showing with ultrasonography images and blind observation made by three evaluators, who analyzed photos taken before and after 4 months of cryolipolysis.

The presence of inflammation was particularly evident in the first thirty days, reinforcing the findings of Know et al. (19), which showed peak inflammation around the 15th and 30th day after the cryolipolysis treatment and the reduction of fat tissue may be observed until the 90th day after treatment. In opposition, the fibrosis, was more intense in the second month, confirming Krueger et al. (2), who stated that in their study, 2-3 months after treatment, the interlobular septa were noticeably thickened, while the inflammatory process presented a milder form and the volume of fat in the treated area had apparently decreased.

At the end of the research it was found that the best results were noted in patients who had lower amount of abdominal fat. Changes in the body contour were not observed in obese patients, confirming what Ferraro et al.⁸ found in their clinical trials, which showed cryolipolysis results are more visible in patients with discrete localized fat.

Furthermore, for the application of cryolipolysis, it was necessary to set a single standard applicator size and parameters for all patients (as recommended by most manufacturers). However, this was not enough to cover the needs of those who had a larger/thicker fat area due to equipment limitations which did not include features/settings for individual parameters such as the cooling intensity factor (CIF), a feature of other machines which consists of temperature control through analysis of local power amount. Thus, the ineffective response in patients who have an increased amount of adipose tissue may be explained by the inadequate temperature for the assigned area to be treated and the vacuuming difficulty found in traction of minimal amount of tissue for treatment, with both the amount of fat and fibrosis that involves the dense and resistant skin region. Stevens and Bachelor (17), observed that the areas with fibrous fat, such as thighs, stand as a challenge, as this type of fat is not easily pulled by vacuum suction.

Another negative factor was the selection of a heterogeneous sample as far as weight, circumference and fat density were concerned, as well as the fact that this study evaluated the efficacy of treatment for 2 months only, whereas other clinical studies evaluated it during a larger time frame, as observed in the study conducted by Bernstein et al. (20) (3 months) and Boey et al. (21) with four months' duration, while the effect of cryolipolysis remains active for about 6 months.

Thus, we suggest further research with homogeneous samples, with a longer term for results analysis and use of equipment with no CIF, to seek ways to manually control the parameters, but in a precise and individualized fashion. The kind of equipment is widely used in South America for its low cost.

In conclusion, it was possible to verify the effectiveness of cryolipolysis in reducing abdominal circumference and of fat layer thickness, as both were statistically significant. As of body weight, it presented variation during

the study, with significant reduction, which corroborates with previous published studies. Being cryolipolysis a local procedure, it does not interfere in the body weight of individuals. The presence of inflammation and fibrosis coincides with literature findings and leads to the conclusion that the mechanism of action is related to apoptosis and procedure-involved (5, 6, 14, 16, 19, 21).

According to photogrammetry results, it may be concluded that cryolipolysis modified the body contour of subjects of lower body mass, justifying the fact that the parameters need to be suited to the individual needs of each patient.

Acknowledgements: We thank the volunteers who contributed with their participation in this study. We also extend our recognition to Potiguar University, Natal, Brazil and to Dr. Jung Siung Camelo Dantas, MD, ultrasonographer, whose contributions were very valuable.

REFERENCES

1. You JS, Chung YE, Baek SE, Chung SP, Kim MJ. Imaging Findings of Liposuction with an Emphasis on Postsurgical Complications. *Korean J Radiol.* 2015;16(6):1197-1206.
2. Krueger N, Mai SV, Luebberding S, Sadick NS. Cryolipolysis for noninvasive body contouring: clinical efficacy and patient satisfaction. *Clin Cosmet Investig Dermatol.* 2004;26(7):201-5.
3. Meyer PF, Carvalho, MGF, Andrade LL, Lopes RNS, Delgado AM, Araújo HG et al. Efeitos da ultracavitação no tecido adiposo de coelhos. *Fisioterapia Brasil.* 2012;13(2):113-8.
4. Stevens WG. Does Cryolipolysis Lead to Skin Tightening? A First Report of Cryodermadstringo. *Aesthetic Surgery Journal.* 2014;34(6):32-4.
5. Sasaki GH, Abelev N, Tevez-Ortiz A. Noninvasive Selective Cryolipolysis and Reperfusion Recovery for Localized Natural Fat Reduction and Contouring. *Aesthetic Surgery Journal.* 2014;34(3):420-31.

6. Manstein D, Laubach H, Watanabe K, Anderson RR. A novel cryotherapy method of non-invasive, selective lipolysis. *Lasers Surg Med.* 2008; S20(40):104.
7. Preciado J, Allison J. The effect of cold exposure on adipocytes: examining a novel method for the noninvasive removal of fat. Oral presentation at the society for cryobiology annual meeting. 2008;57(3):327-27.
8. Ferraro GA, Francesco F, Cataldo C, Rossano F, Nicoletti G, D'Andrea F. Synergistic Effects of Cryolipolysis and Shock Waves for Noninvasive Body Contouring. *AesthPlastSurg.* 2012;36(3):666-79.
9. Shek SY, Chan NPY, Chan HH. Non-Invasive Cryolipolysis for Body Contouring in Chinese—A First Commercial Experience. *Lasers in Surgery and Medicine.* 2012;44:125–130
10. Meyer PF, Mendonça AG, Rodrigues RD, Corradi DP, Cruz LB, Antunes MJ et al. Protocolo de avaliação fisioterapêutica em adiposidade localizada. *Fisioterapia Brasil: suplemento especial.* 2008;26-31.
11. Chopra K, Tadisina KK, Stevens WG. Cryolipolysis in Aesthetic Plastic Surgery. www.ePlasty.com, Interesting Case Series. 2014
12. Mendonça AMS, Pádua M, Ribeiro AP, Milani GB, João SMA. Confiabilidade intra e interexaminadores da fotogrametria na classificação do grau de lipodistrofia ginóide em mulheres assintomáticas. *Fisioterapia e Pesquisa.* 2009;16(2):102-6
13. González-Suárez A, Gutierrez-Herrera E, Berjano E, Jimenez Lozano JN, Franco W. Thermal and Elastic Response of Subcutaneous Tissue With Different Fibrous Septa Architectures to RF Heating: Numerical Study. *Lasers in Surgery and Medicine.* 2015;47(2):183–95.
14. Ingargiola MJ, Motakef S, Chung MT, Vasconez HC, Sasaki GH. Cryolipolysis for Fat Reduction and Body Contouring. *Plastic And Reconstructive Surgery.* 2015;135(6):1581-90.
15. Zelickson BD, Burns AJ, Kilmer SL. Cryolipolysis for safe and effective inner thigh fat reduction. *Lasers Surg. Med.* 2015;47(2):120-127.
16. Brightman L, Geronemus R. Can second treatment enhance clinical results in cryolipolysis? *Cosmetic Demartology.* 2011;24(2):85-88.
17. Stevens WG, Bachelor EP. Cryolipolysis Conformable-Surface Applicator for Nonsurgical Fat Reduction in Lateral Thighs. *Aesthetic Surgery Journal.* 2015;35(1):66-71.
18. Coleman SR, Sachdeva K, Egbert BM, Preciado J, Allison J. Clinical efficacy of noninvasive cryolipolysis and its effects on peripheral nerves. *Aesthetic Plast Surg.* 2009;33(4):482-8.
19. Kwon TR, Yoo KH, Oh CT, Shin DH, Choi EJ, Jung SJ, et al. Improved methods for selective cryolipolysis results in subcutaneous fat layer reduction in a porcine model. *Skin Res Technol.* 2015;21(2):192-200.
20. Bernstein EF, Bloom JD, Basilavecchio LD, Plugis JM. Non-invasive fat reduction of the flanks using a new cryolipolysis applicator and overlapping, two-cycle treatments. *Lasers Surg Med.* 2014;46(10):731-5.
21. Boey GE, Wasilenchuk JL. Enhanced clinical outcome with manual massage following cryolipolysis treatment: A 4-month study of safety and efficacy. *Lasers Surg Med.* 2014;46(1):20-6